ISSN (O) : 2582-3271
PubMed-National Library of Medicine - ID: 101766917

International Journal of Dental Science and Clinical Research (IJDSCR)

Dr. Angel Vaidic Publication

Available Online at: http://www.ijdscr.org

Volume 3, Issue 4, August - 2021, Page No. : 58 - 73

Treatment of an Adult Pseudo-Class III with Maxillary Expansion and Mandibular Incisor Extraction – A Case Report

Dr. Nilanjana Sarkar, MDS, Associate professor, Kusumdevi Sunderlal Dugar, Jain Dental College, Cossipore, Kolkata, India

Dr. Sumit Goel, MDS, Consultant, Apollo Clinic, Gorakhpur, Uttar Pradesh, India

Dr. Karunakara B.C., MDS, Professor, Department of Orthodontics, KLE Society's Institute of Dental Sciences, Yeshwanthpur Suburb, Bangalore, Karnataka, India

Citation of this Article: Dr. Nilanjana Sarkar, Dr. Sumit Goel, Dr. Karunakara B.C., "Treatment of an Adult Pseudo-Class III with Maxillary Expansion and Mandibular Incisor Extraction – A Case Report,'' IJDSCR – August – 2021, Vol. – 4, Issue - 4, P. No. 58-73.

Corresponding Author: Dr. Nilanjana Sarkar, MDS, Associate professor, Kusumdevi Sunderlal Dugar, Jain Dental College, Cossipore, Kolkata, India

Type of Publication: A Case Report

Conflicts of Interest: Nil

Abstract

Pseudo–Class III malocclusion has been identified with anterior crossbite as a result of mandibular displacement. Premature contact between the maxillary and mandibular incisors results in forward displacement of the mandible in this type of malocclusion.Diagnosis of pseudo-class III in an adult dentition becomes difficult due to the establishedincisor interference - proclined mandibular and retroclined maxillary incisors. This case report presents a 22 year old female patient with pseudo-class III malocclusion presenting with retrusive upper lip, anterior crossbite involving three teeth, periodontally compromised mandibular right central incisor and severe crowding in upper and lower anterior segments. The patient was treated with expansion of maxillary arch and extraction of mandibular right central incisor. The treatment resulted in an improved profile with positive overjet and overbite.

Keywords

Pseudo-class III malocclusion, Arch expansion, Single lower incisor extraction

Introduction

Pseudo-class III malocclusion as defined by Moyers is a positional malrelationship with an acquired

neuro-muscular reflex.[1,4] It is associated with anterior crossbite as a result of mandibular displacement.[1] Tweedclassified Class III malocclusion into 2 categories: CategoryA and Category B, where Category A was defined as pseudo–Class III malocclusion with a conventional shape mandible.[5] Incisor interference in this malocclusion leads to proclined mandibular and retroclined maxillary incisors[2,3]; this in turn poses difficulty in diagnosing the mandibular path of closure in adult pseudo-class III cases. Rabie et al outlined the diagnostic criteria for pseudo-class III malocclusionin southern Chinese children as decreased midface length, forward position of mandible with normal mandibular length, retroclined upper incisors, normal lower incisors and retrusive upper lip.[5-7]In adult pseudo-class III cases showing severe anterior maxillary crowding and anterior crossbite, maxillary alveolar expansion is a viable option, in the absence of posterior crossbite.

Identifying the skeletal and dental components of a pseudo-class III malocclusion is important in the treatment approach, especially in an adult patient. Several aspects must be considered, such as periodontal health, orthodontic mechanics, functional and esthetic alterations, and treatment stability. The presence of gingival and bone recession may limit large orthodontic movements. There are situations in which atypical extractions facilitate mechanics, preserve periodontal health and favor maintenance of the facial profile, which tends to unfavorably change due to facial changes with age.[8] The extraction of a lower incisor, in selected cases, is an effective approach. Mandibular incisor extraction has been advocated by some authors to help increase stability without prolonged retentionespecially in cases of loss of labial gingiva or bone[16], mandibular Bolton excess[17,18] and in class III tendency.[19]Treatment of adult pseudo-class III with mandibular incisor extraction concurrently with maxillary arch expansion is an uncommon condition rarely reported in literature. So the purpose of this case reportwas to present and discuss the treatment of an adult patient with pseudo-class III malocclusion presenting with retrusive upper lip, anterior crossbite involving three teeth, periodontally compromised mandibular right central incisor and severe crowding in upper and lower anterior segments.

Diagnosis and Etiology

A 21-year-old woman came to the department of orthodontics with a chief complaint of irregularities and crowding in upper and lower arches. Her extraoral examination showed a retrusive upper lip. The intraoral examination showed Angle's class I molar relationship bilaterally with anterior crossbite involving three teeth, severe crowding in upper and lower anterior segments and labial root prominence of mandibular right lateral incisor. There was no history of any medical illness. The panoramic radiograph showed mandibular right lateral incisor with radiolucency extending to the root apex suggesting extensive vertical bone loss.

Treatment Objectives

The treatment objectives were

1. Elimination of the anterior crossbite
2. Correction of the maxillary and mandibular arch length discrepancies
3. Decrowding of upper and lower anterior segments and elimination of the Bolton discrepancy by upper arch expansion and lower single incisor extraction
4. Improvement of the periodontal health of lower incisors
5. Restoration of an esthetic lip profile
6. Esthetic restoration of the incisal edges and teeth discoloration.

Treatment Alternatives

Based on the treatment objectives two treatment options were presented to the patient –

1. Proclining the upper incisors without upper arch expansion with no extraction in lower arch

   Or

2. Upper arch expansion with one single lower incisor extraction.

A diagnostic wax-up was performed to weigh the occlusal possibilities; it showed that a non-expansion and non-extraction approach would not improve the occlusion and the end-result was unlikely to be stable. Thus the options and their possible outcomes were explained to the patient who chose the second option.

Treatment Progress

Hyrax appliance(hygienic rapid expander, Leone) was bonded through an acrylic bite block covering the premolars till the second molar. The appliance was activated once a day by one turn(one-fourth of the diameter of the screw).

The classic midline diastema usually seen after upper arch expansion was not observed. However the crowding was alleviated.

After the completion of the expansion, MBT (3M UNITEK) prescription 0.022” x 0.028” brackets were bonded in upper and lower arches. Extraction of the lower incisor was postponed till the alignment of the upper incisors as the amount of overjet which could be obtained was still unknown.

Treatment Results

The treatment regimen of arch expansion with lower single incisor extraction resulted in a favourable inter-arch relationship, relief of the anterior crossbite, normal overjet and overbite, good periodontal health of lower incisors and dramatic improvement in the facial profile.

Discussion

Pseudo-class III patients, especially the adult ones pose a problem in diagnosis. In extraoralphotos the profile of these patients appear quite normal at centric relation (CR) and slightly concave at habitual occlusion (HO).[1,6]Rabie et al outlined the diagnostic criteria for pseudo-class III malocclusion in southern Chinese children as decreased midface length, forward position of mandible with normal mandibular length, retroclined upper incisors, normal lower incisors and retrusive upper lip.[7] Some previous studies have outlined the dental features of skeletal Class III malocclusion with protrusive maxillary incisors and retrusive mandibular incisors.[1,4,6]

Unwanted side-effects of lower incisor extraction have been reported by some authors as increase in overbite and overjet beyond acceptable limits, space reopening, unsatisfactory posterior occlusion, recurrence of crowding and/or rotations in lower anterior region and unesthetic loss of the interdental gingival papillae in the mandibular anterior region.[9-15]

Conclusions

The current treatment modality was satisfactory in treating the patient and achieving the treatment objectives.

References

1. Lee BD. Correction of crossbite. Dent Clin North Am 1978;22:647-68
2. Gravely JF. A study of the mandibular closure path in Angle Class III relationship. Br J Orthod 1984;11:85-91.
3. Graber TM, Rakosi T, Petrovic AG. Dentofacial orthopedics with functional appliance, 2nd edition. St Louis: Mosby; 1997. p. 462-70.

4. Moyers RE. Handbook of orthodontics, 4th edition. Chicago: Year Book; 1988. p. 410-5.
5. Tweed CH. Clinical Orthodontics. St Louis: Mosby; 1966. p. 715-26.
6. Sharma PS, Brown RV. Pseudo mesiocclusion: diagnosis and treatment. J Dent Child 1968;35:385-92.
7. Rabie ABM and Gu Yan. Diagnostic criteria for pseudo-class III malocclusion. Am J Orthod Dentofacial Orthop 2000;117:1-9.
8. Barbosa VLT. Angle class I malocclusion treated with lower incisor extraction. Dental Press J Orthod. 2013;18(3):150-8.
9. Dacre JT. The long term effects of one lower incisor extraction. Eur J Orthod1985;53:706-13.
10. Richardson ME. Extraction of lower incisors in orthodontic treatment planning. DentPract 1963;14:151-6.
11. Valinoti JR. Mandibular incisor extraction therapy. Am J Orthod Dentofacial Orthop 1994;105:107-16.
12. Klein DJ. The mandibular central incisor, an extraction option. Am J Orthod Dentofacial Orthop 1997;111:253-9.
13. Kokich VG, Shapiro PA. Lower incisor extraction in orthodontic treatment: four clinicalreports. Angle Orthod 1984;54:139-53
14. Canut JA. Mandibular incisor extraction: indications and long-term evaluation. Eur J Orthod 1996;18:485-9.
15. Uribe F, Holliday B, Nanda R. Incidence of open gingival embrasures after mandibular incisor extractions : a clinical photographic evaluation. Am J Orthod Dentofacial Orthop 2011;139:49-54.
16. Riedel RA, Little RM, Bui TD. Mandibular incisor extraction: postretention evaluation of stability and relapse. Angle Orthod 1992;62:103-16.
17. Schuberth G, Shaughnessy T, Timmis D. Mandibular advancement and reduction genioplasty: case report. Am J Orthod Dentofacial Orthop 1990;98:481-7.
18. Owen AH. Single lower incisor extractions. J Clin Orthod 1993;27:153-60.
19. Bahreman AA. Lower incisor extraction in orthodontic treatment. Am J Orthod 1977;72:560-7.
20. Handelman CH. Nonsurgical rapid maxillary expansion in adults:a clinical evaluation. Angle Orthod 1997;67(4):291-308.

Figure legends

Figure - 1a, 1b, 1c, 1d, 1e – Pre-treatment intraoral photos

Figure - 2a, 2b, 2c, 2d – Pre-treatment extraoral photos

Figure - 3a, 3b – Pre-treatment lateral cephalogram and Orthopantomograph

Figure - 4 – Rapid Maxillary Expansion appliance bonded to upper teeth

Figure - 4a, 4b, 4c – Post-expansion intraoral photos of upper arch

Figure - 5a, 5b, 5c, 5d, 5e – Alignment and levelling and space closure completed.

Figure - 6a, 6b – Settling with w elastics

Figure - 7a, 7b, 7c, 7d, 7e – Posttreatment intraoral photos

Figure - 8a, 8b, 8c, 8d – Posttreatment extraoral photos

Figure - 9a, 9b – Posttreatment lateral cephalogram and Orthopantomograph

1a

1b

1c

1d

1e

2a

2b

2c

2d

3a

4

4a

4a-1

4b

4c

5a

5b

5c

5d

5e

6a

6b

7a

7b

7c

7d

7e

8a

8b

8c

8d

9a

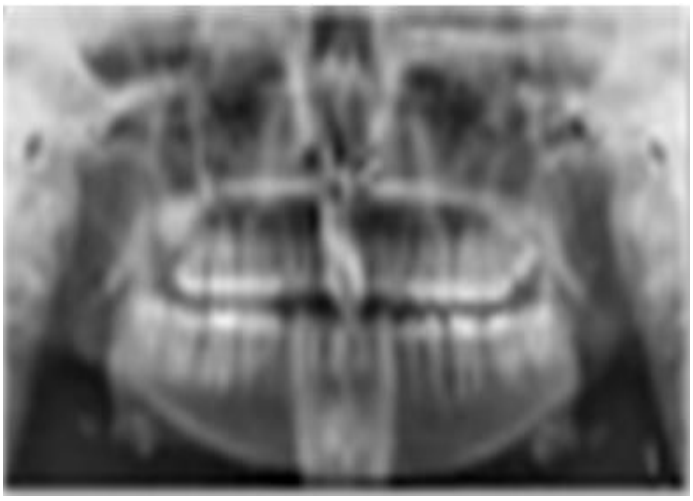

9b